

# Flex-i-Nail

## Introduction

The current ESIN nail supplied to you is the latest evolution of the various nails designed over the years starting back in 1961 With Prof PREVOT, Prof LASCOMBES and Dr METAIZEAU when they introduced the Nancy Nail to the market.

Having varied over the years this final version is the choice of the first purely paediatric orthopaedic company ever founded based in Warsaw Indiana.

The techniques for its use are identical to the techniques used before for any of the ESIN designs excepting this ESIN nail, the Flex-i-nail comes with protective caps in order to avoid minor complications due to friction and swellings which can be induced due to the fact that these nails come mono-length and are cut to length intra-operatively.


## Product description:

The Flex-i-nail is available in different version. The version used in Denmark is a TA6v titanium flexible version color coded available in 5 diameters. 2-2.5-3-3.5-4mm These nails are completed by twin sets of protective caps also of TA6V titanium and of the same diameters matching the same color code.

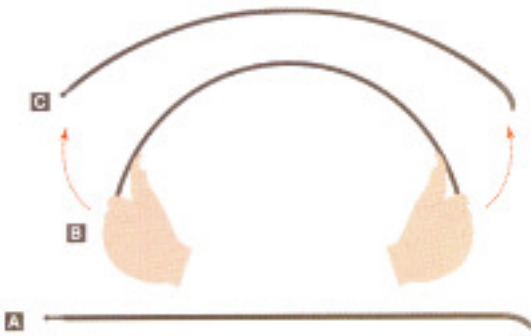
## The indications for us :

Femoral and forearm child fractures (for children aged 6 to 14 years old)

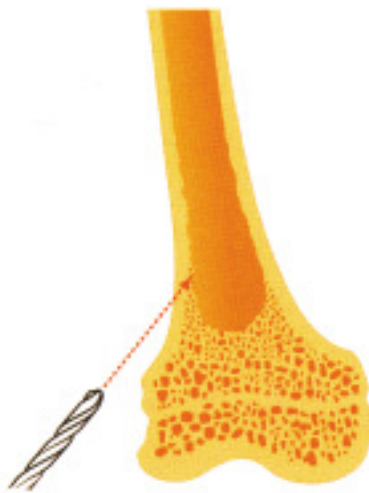## INSTRUCTIONS FOR USE



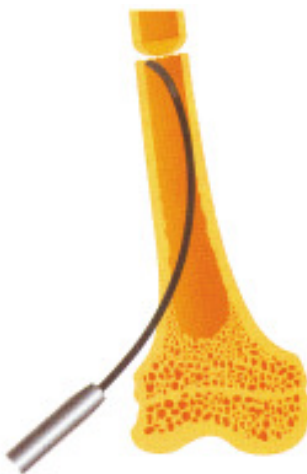**NAIL SIZING:** Position the patient on the fracture table using the correct size boot. Reduce the fracture. Choose the nail length by measuring the distance between the distal growth plate and the lower part of the greater trochanter growth plate. It may help to identify the growth plate by marking the skin with a marker pen. Then cut two nails to length using an appropriate shear or bench cutter. Try and avoid leaving too great a burr.



**BEND THE NAILS** : Bend both nails approximately 30° ensuring the maximum part of the curvature is at the level of the fracture. The curvature of both nails must be the same.



**SKIN INCISION & ENTRY HOLE:** You can start either side. Make the skin incision distal to the intended entry hole. The medial and lateral holes must be level with one another. Use a drill about 2mm larger than the nail diameter selected and make the entry holes 2cms above the growth plate and as oblique as possible. This will aid the passage of the nails.



**PASSING THE 1<sup>st</sup> NAIL** : Put the introducer or Jacob's truck onto the nail passing it up as far as possible. Pass the nail into the medullary canal and move it up the canal by a left to right rotating movement and pulling it and pushing it back and forth. STOP AT THE FRACTURE SITE. Note that the FLEX-i-Nail compared to other devices has a modern reduced profile spatula design making introduction easier while maintaining flexibility. With other nail designs it is possible that even with the right choice of nail one has to pass to a thinner diameter because the spatula of the nail is too curved.



**PASSING THE 2<sup>nd</sup> NAIL:** Pass the second nail with the same introducer or Jacob's truck using the same technique as for the 1<sup>st</sup> nail. Also STOP at the fracture site.



**PASSING THE NAILS ACROSS THE FRACTURE:** Reduce the fracture and slightly tap both nails across to the opposite fragment. Continue to pass the nail as far as possible with the introducer or the Jacob's truck.



**FINAL IMPACTION:** Remove the introducing device and impact the nails with the correct size impactor leaving approximately 2cm of each nail outside the cortex.

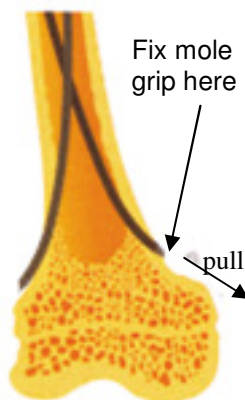


**FINAL POSITION:** The curved tip of the lateral nail should be positioned towards the greater trochanter and the medial nail pointing towards the lesser trochanter.



**AFFIXING THE PROTECTIVE CAPS:** if a clean cut was obtained slip a caps still on the bar with both caps onto the nail. If there is a slight burr slant the cap on the same side as the burr slip the cap onto the nail and snap off the cap. It snaps off by bending the bar it's on in any direction. Proceed in the same manner for the second nail with the second cap.

**DO NOT SNAP THE CAPS OFF THE BAR BEFORE PUTTING THE CAPS ON THE NAILS**



**NAIL REMOVAL:** Removal of the nails should be undertaken between 3 to 5 months providing x-rays are satisfactory. The nails are removed by applying the nail extractor ( the special stainless steel mole grip) to the part of the nail lying outside of the cortex. If necessary a slap hammer can be attached to the instrument.

**Please Note :**

This document is intended solely for use by orthopaedic surgeons. This operating technique constitutes the recommended procedure for the implantation of ESIN nails in children. BIOMED is only the distributor of the device and has no medical expertise as to recommend or not the use of a procedure nor of a specific implant. In that respect the surgeon is sole responsible for the choice of both the procedure to use and the choice as to which implant and to adapt them to each specific individual. However BIOMED is available at any time in order to help any who require further information concerning this technique